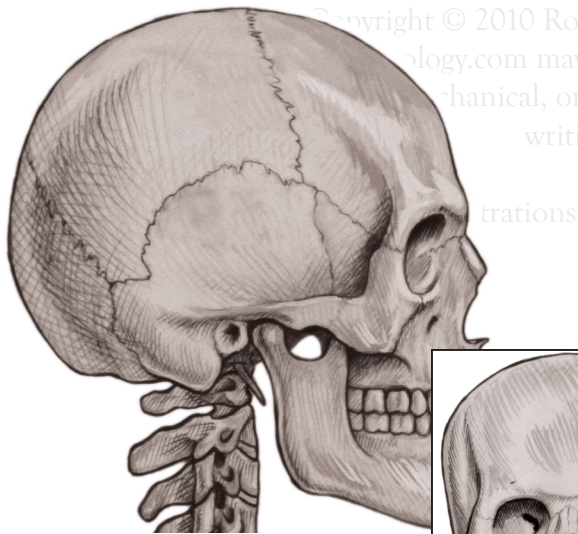


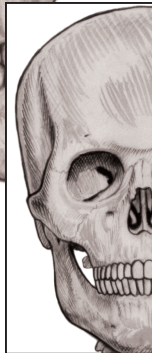Muscles of Mastication

Temporalis m.



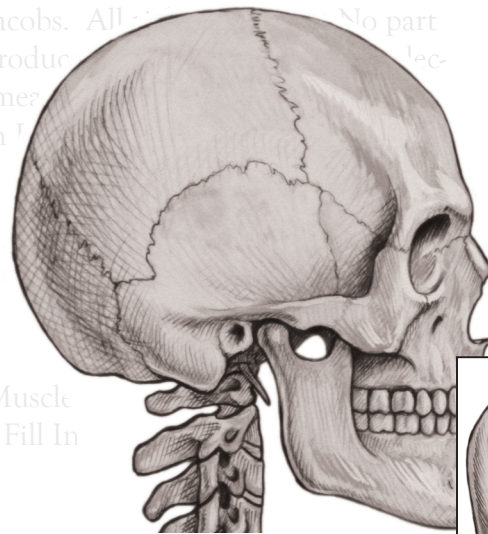
Lateral View

Origin: Temporal fossa and fascia
Insertion: Coronoid p. of mandible b.
Movement: Flexion of TMJ
Innervation: Temporoauricular n.



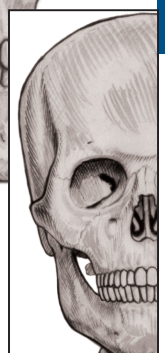
Anterior View

Masseter m.



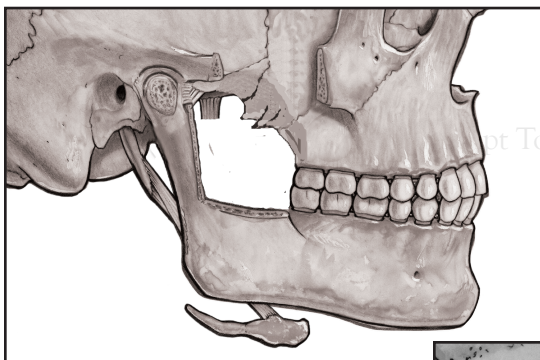
Lateral View

Origin: Zygomatic arch
Insertion: Ramus, angle and coronoid p. of mandible b.
Movement: Elevation
Innervation: Temporoauricular n.



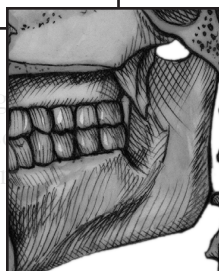
Anterior View

Medial Pterygoid m.



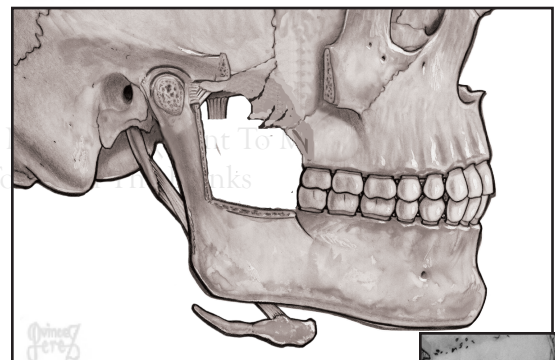
Lateral View

Origin: Medial surface of lateral pterygoid plate, tuberosity of maxilla b.
Insertion: Medial surface of ramus and angle of mandible b.
Movement: Elevation with protraction
Innervation: Mandibular n.



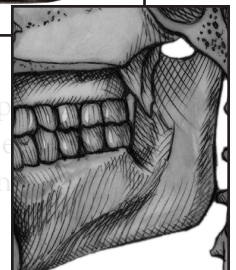
Internal View

Lateral Pterygoid m.



Lateral View

Origin: Infratemporal crest and greater wing of sphenoid b.
Insertion: Condyle of mandible b.
Movement: Extension with protraction
Innervation: Mandibular n.



Internal View